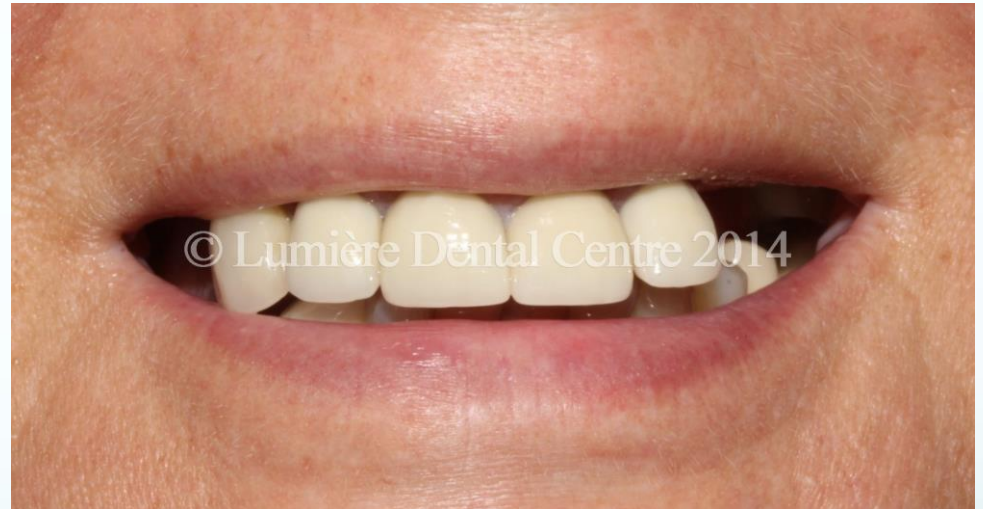

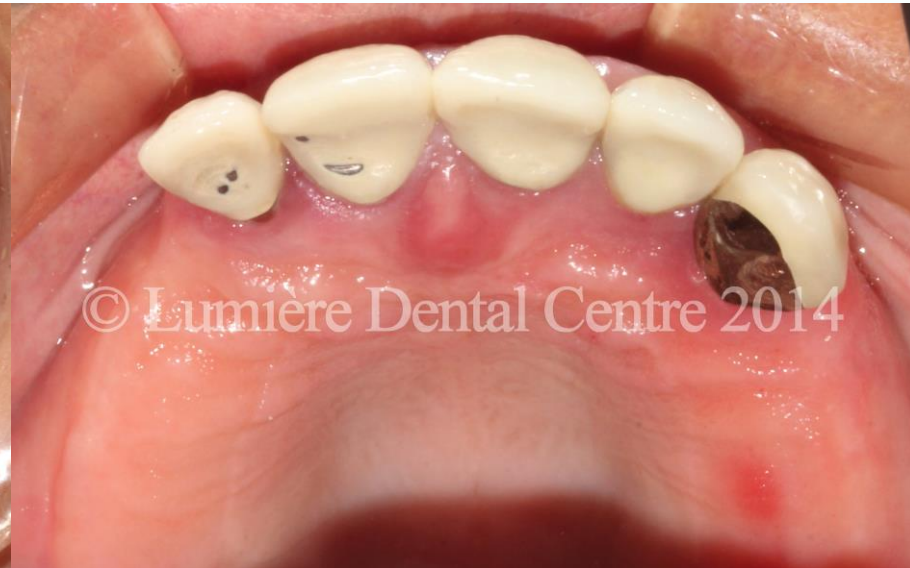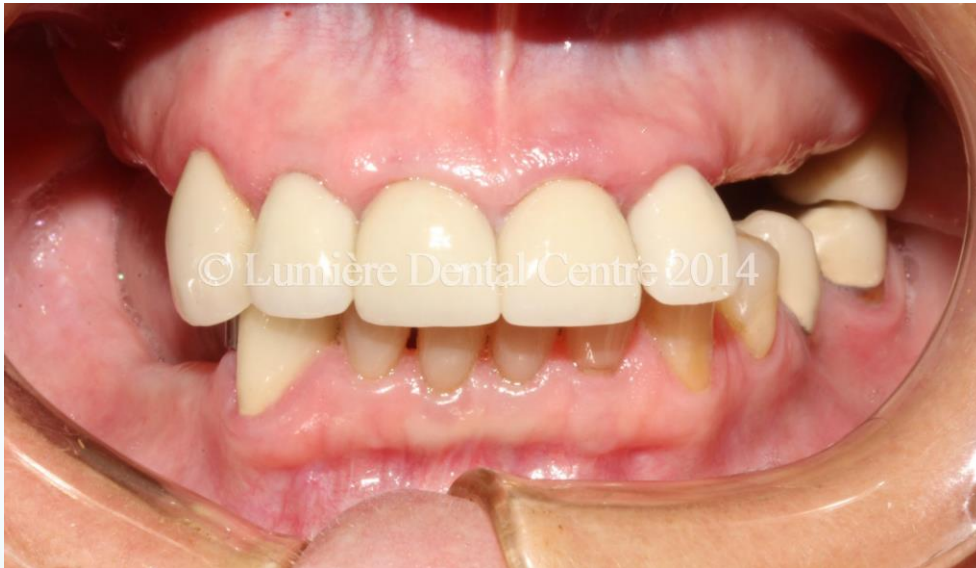Face before procedure

68 Years Old Female wearing RPD restoring missing teeth on the upper and lower archs
The patient is on Antidepressants otherwise fit and well

Chief complaint is that she is tired of her RPDs.
Her smile is “ugly” and teeth are protruding forward .
Failure of the crowns multiple times and recementing them



Clinical Assessment



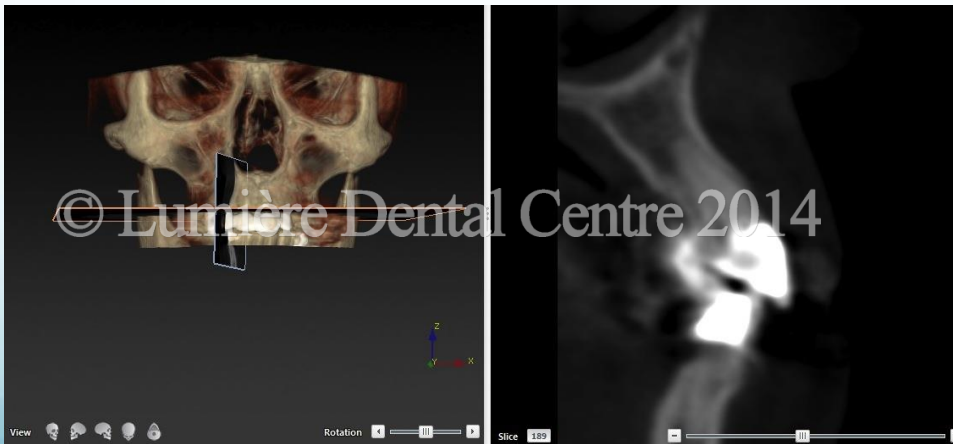
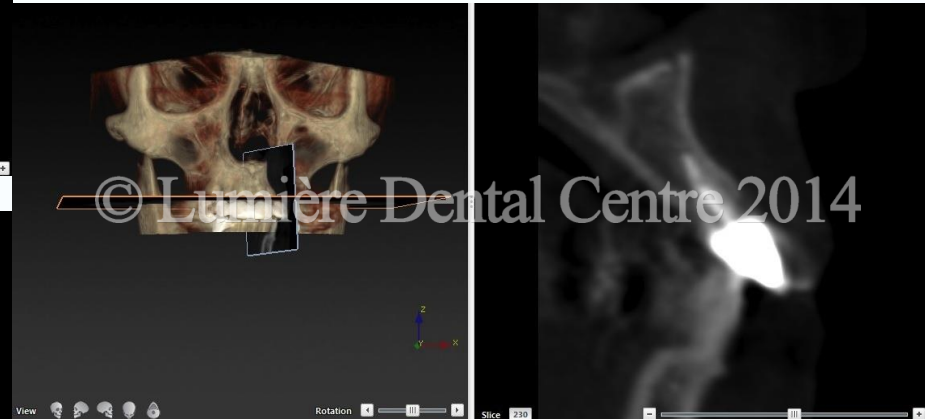
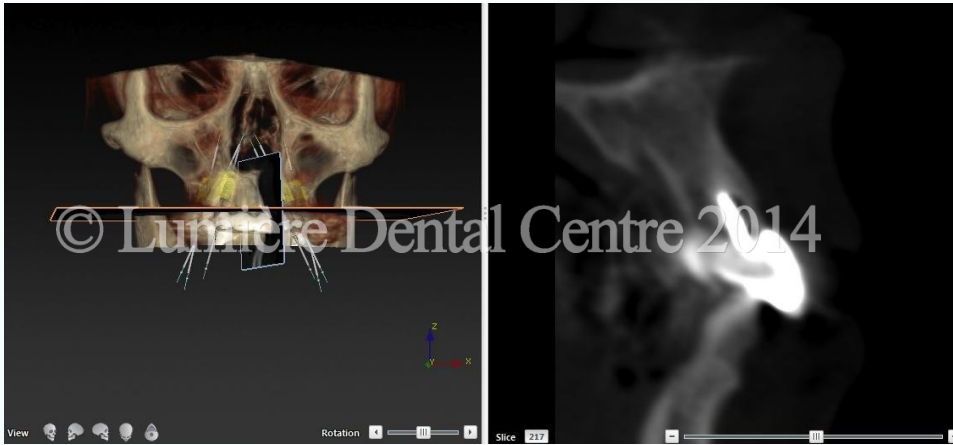
Deep overbite

The 27 is mobile , deep 10 m pocket mesially

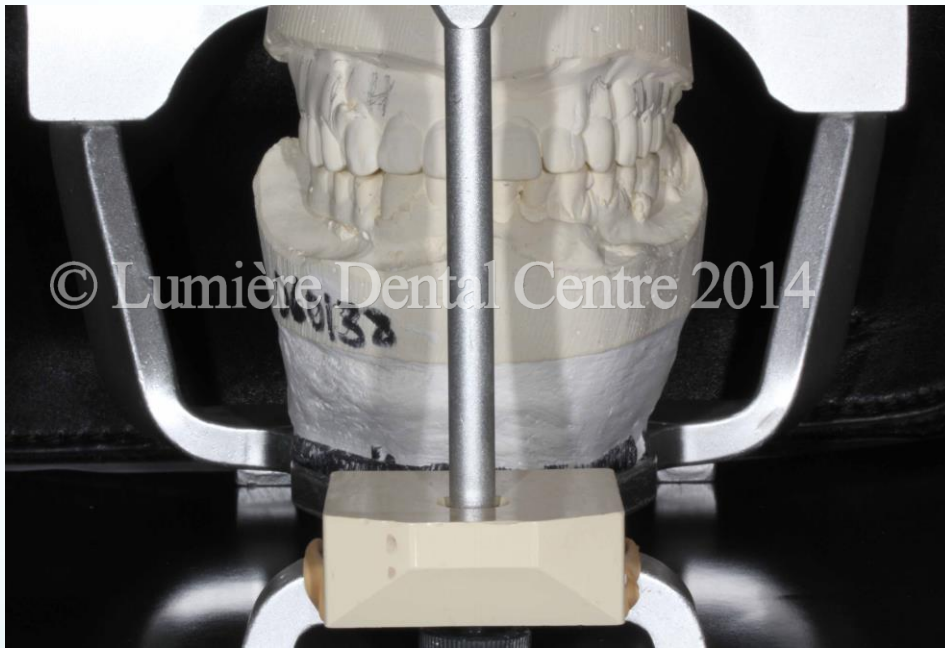
Mobility on 22 crown .

Recurrent decay

Radiographic assessment for the remaining dentition



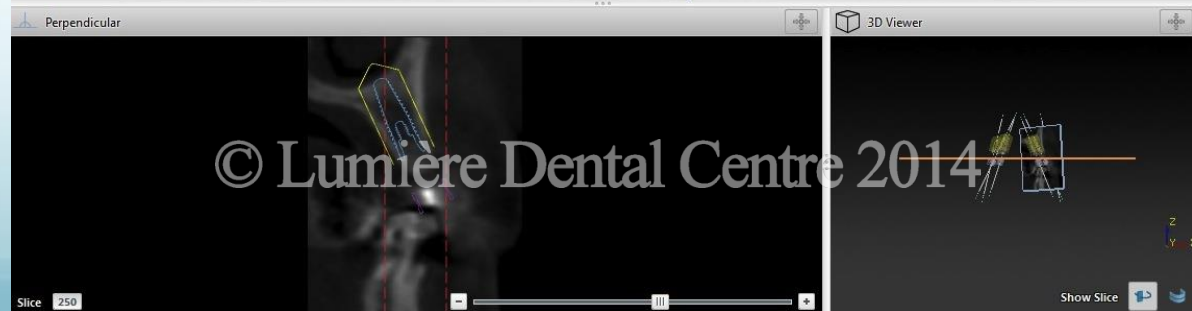
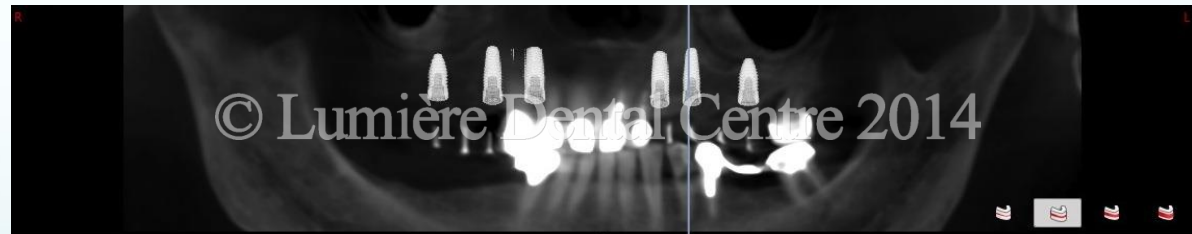
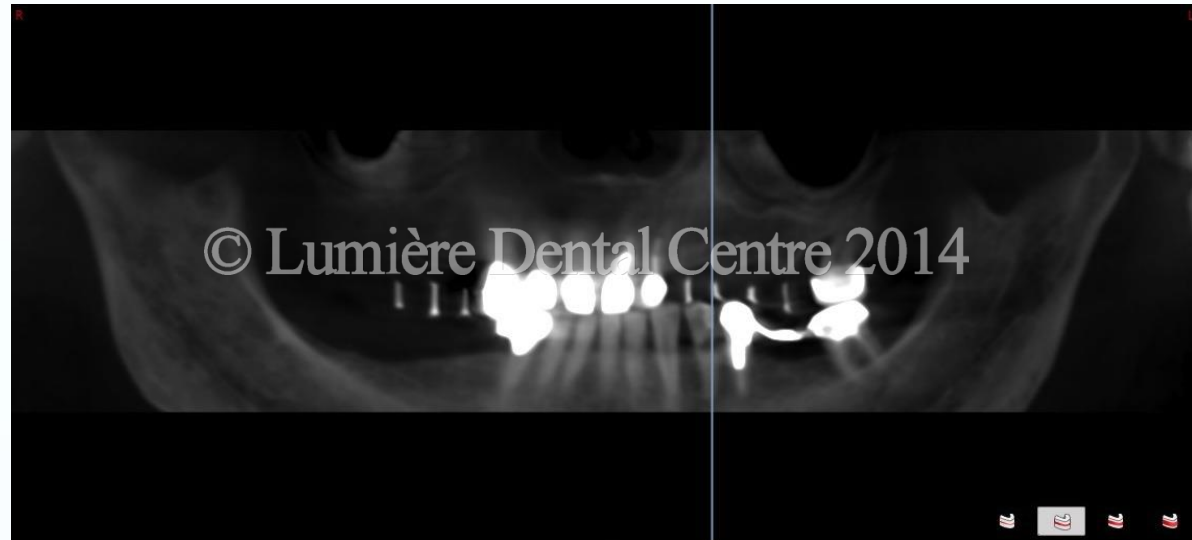
Diagnosics



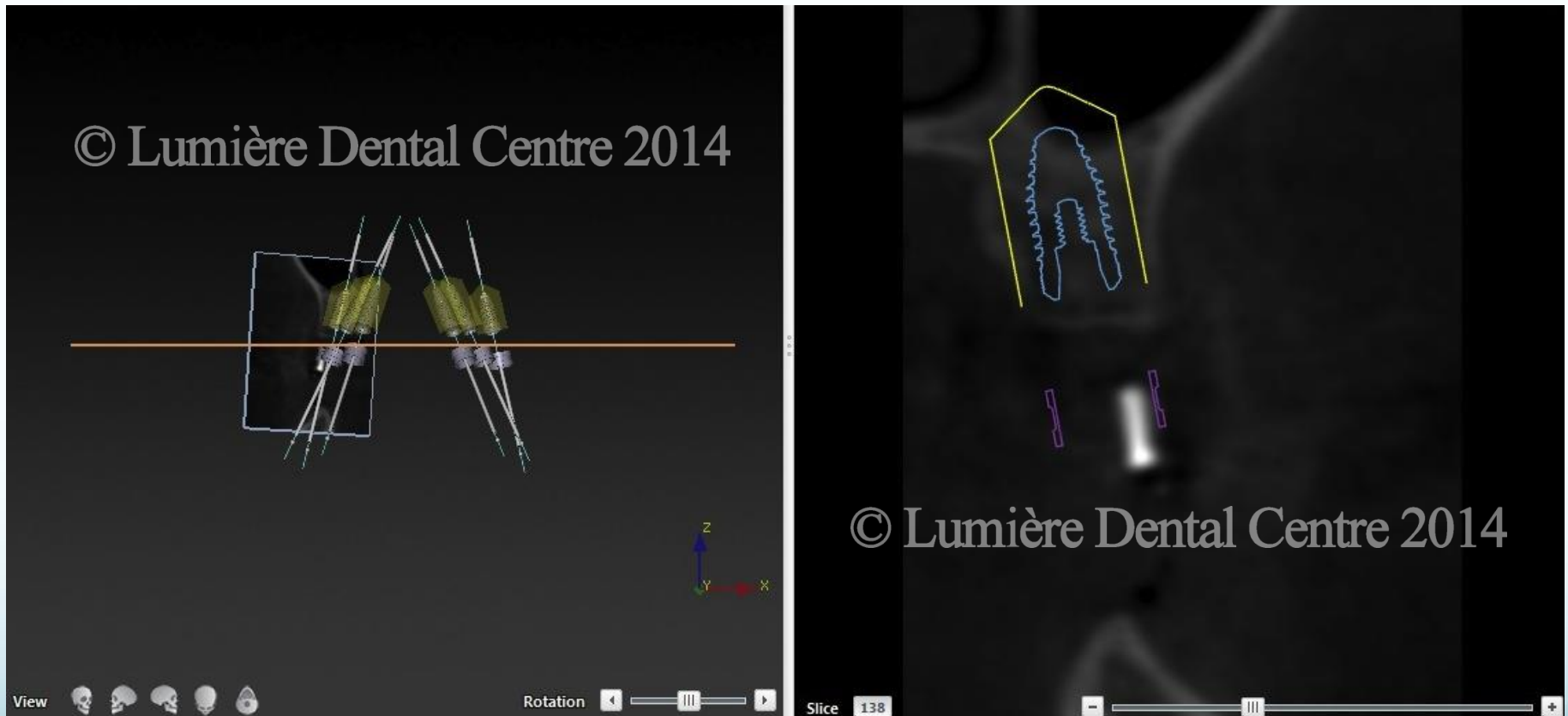
Impressions were taken and mounted on semiadjustable articulators
Two impressions were taken one with RPD`s in place and the other without.

Treatment Planning

Extraction of the problematic remaining dentition except the 27 which will be left in place as reference and for proprioception
Placing 6 implants and internal sinus lifting procedure
Impression taking after 48 hours and placement of screw retained temporary acrylic hybrid prosthesis for 12 months as patient requested

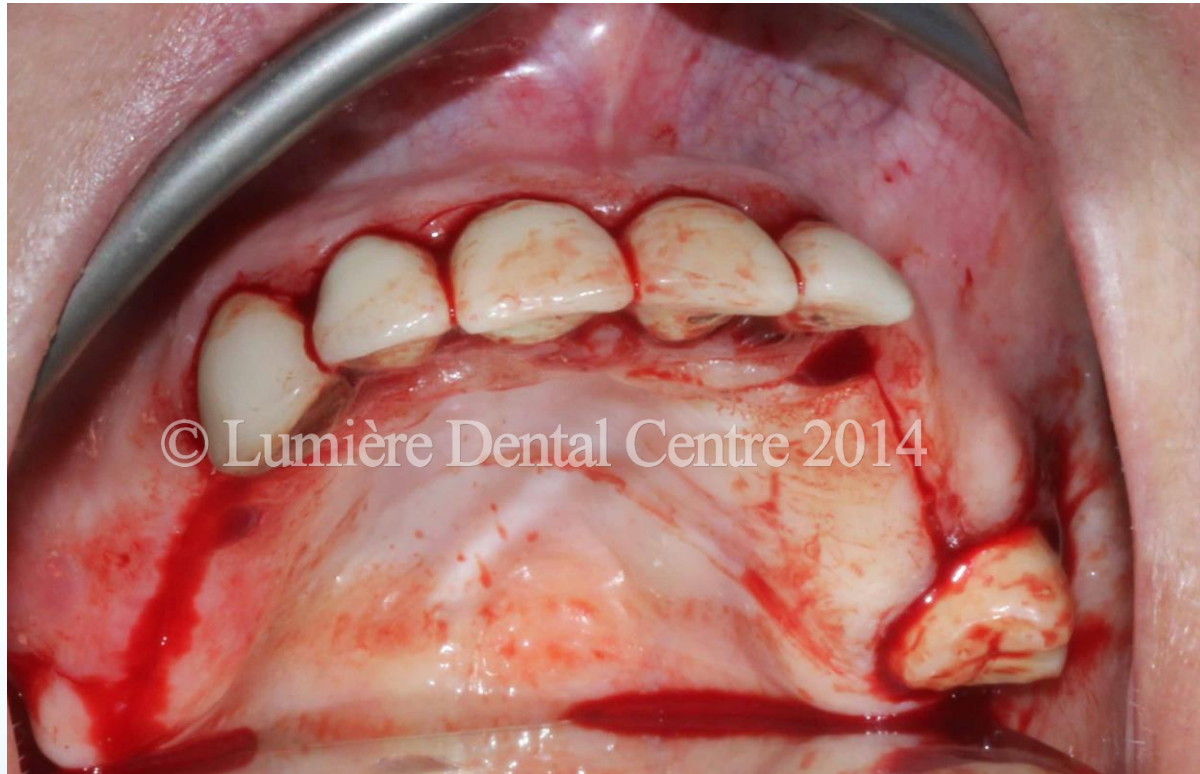

Internal sinus lift Planning



3 mm internal sinus lift on the posterior maxilla on the right and left side

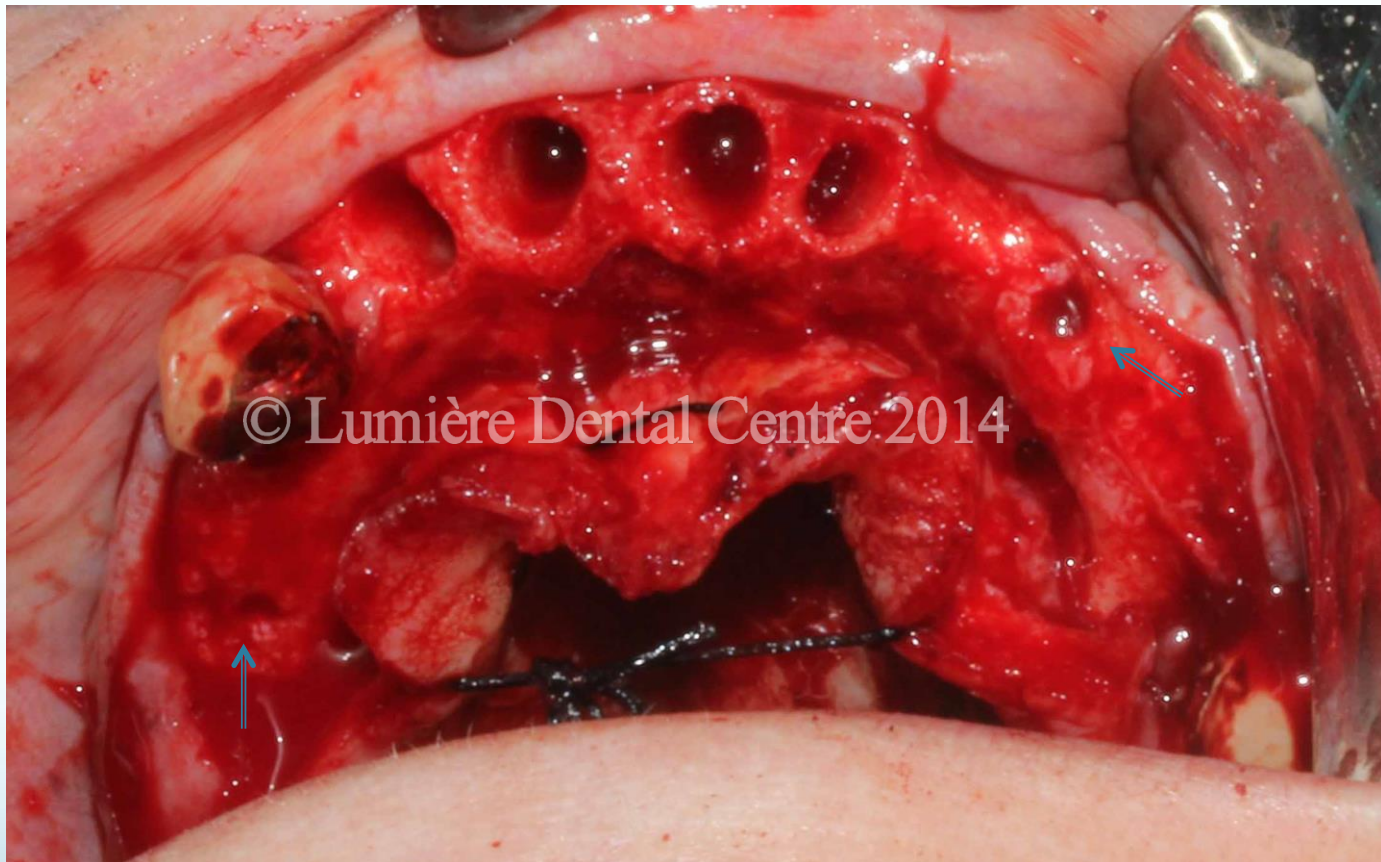Pilot drilling using the guide and Incision



The surgical guide was using initially to determin the ideal location of the implants

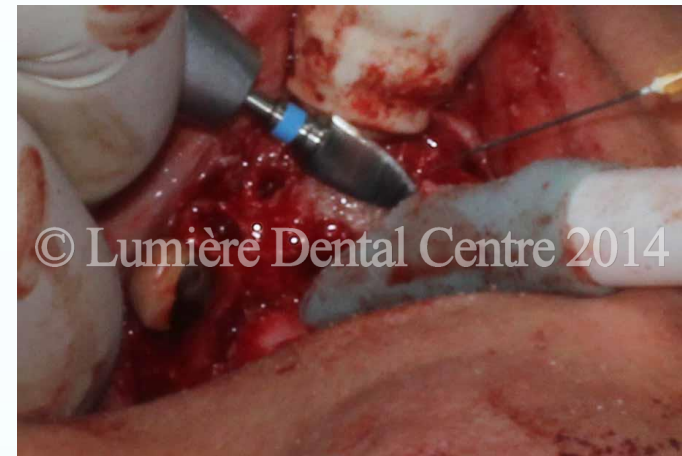
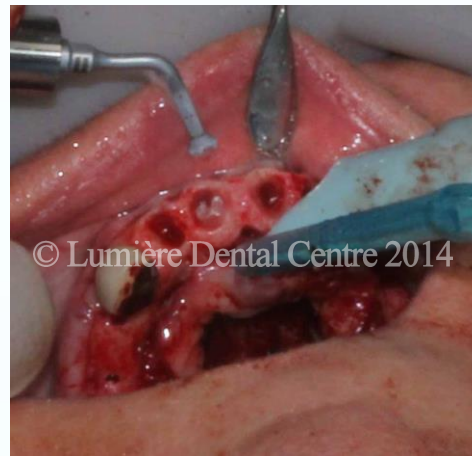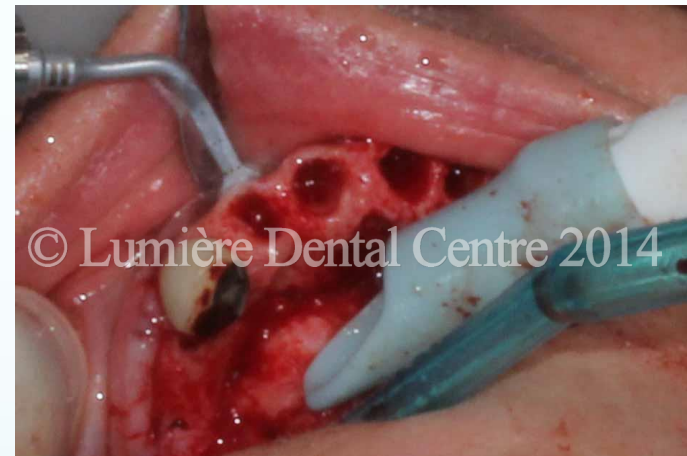Crestal Incision with distal releasing full thickness flap elevation.

After Extraction



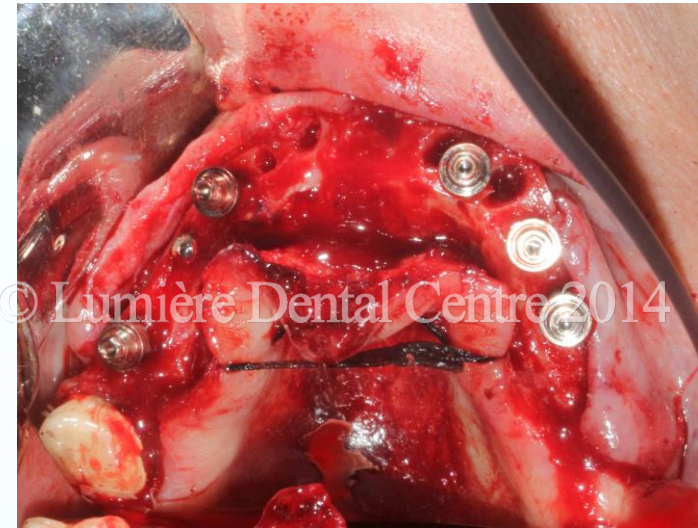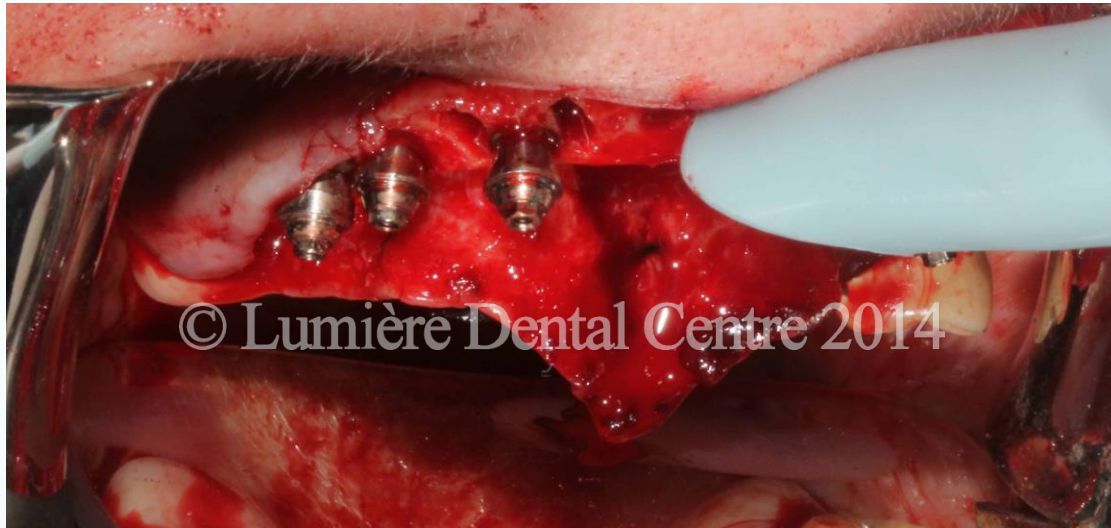
Removal of hopeless teeth and also we can see the location of the initial drilling using the guide

Alveolectomy



Alveolectomy done according the amount of vertical space required , it was done to the minimal of 12 mm so 3 mm was taken from anterior maxilla , 2 mm from the premolar area and 1 mm in the molar area Marking the length of the bone to be removed using Piezo and removal using a surgical bur

Implants Placed



Insertion of 3.8 * 12 mm Biohorizons tapered internal Plus implants in the canine areas

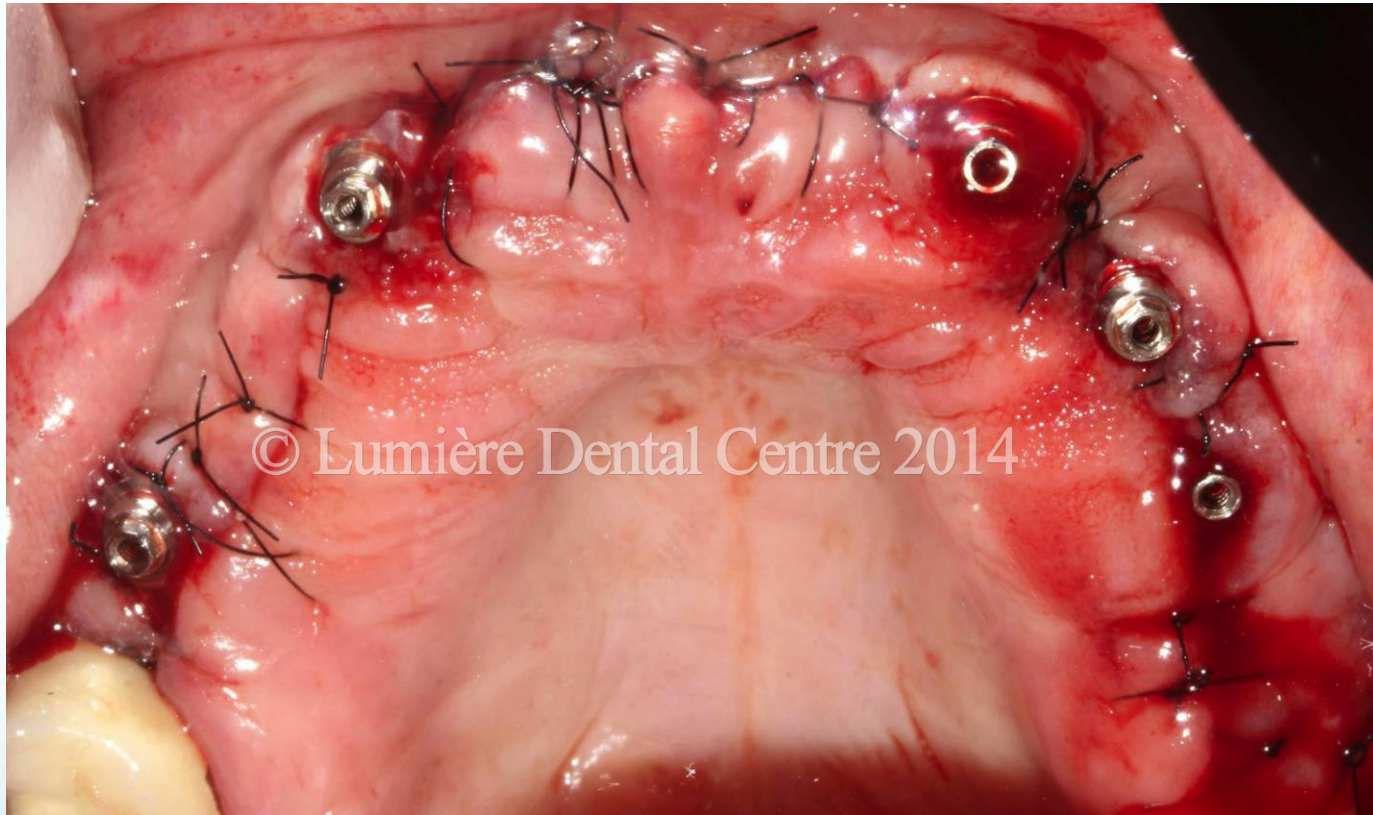3.8 * 10.5 mm in the premolar areas after sinus lift only in the 2nd quad

4.6 * 9 mm in the molar areas after sinus lift on both quadrants

Torque reached on all implants between 50 and 70 NCM except the premolar area implant in the second quadrant and was 30NCM and was decided to submerge it .

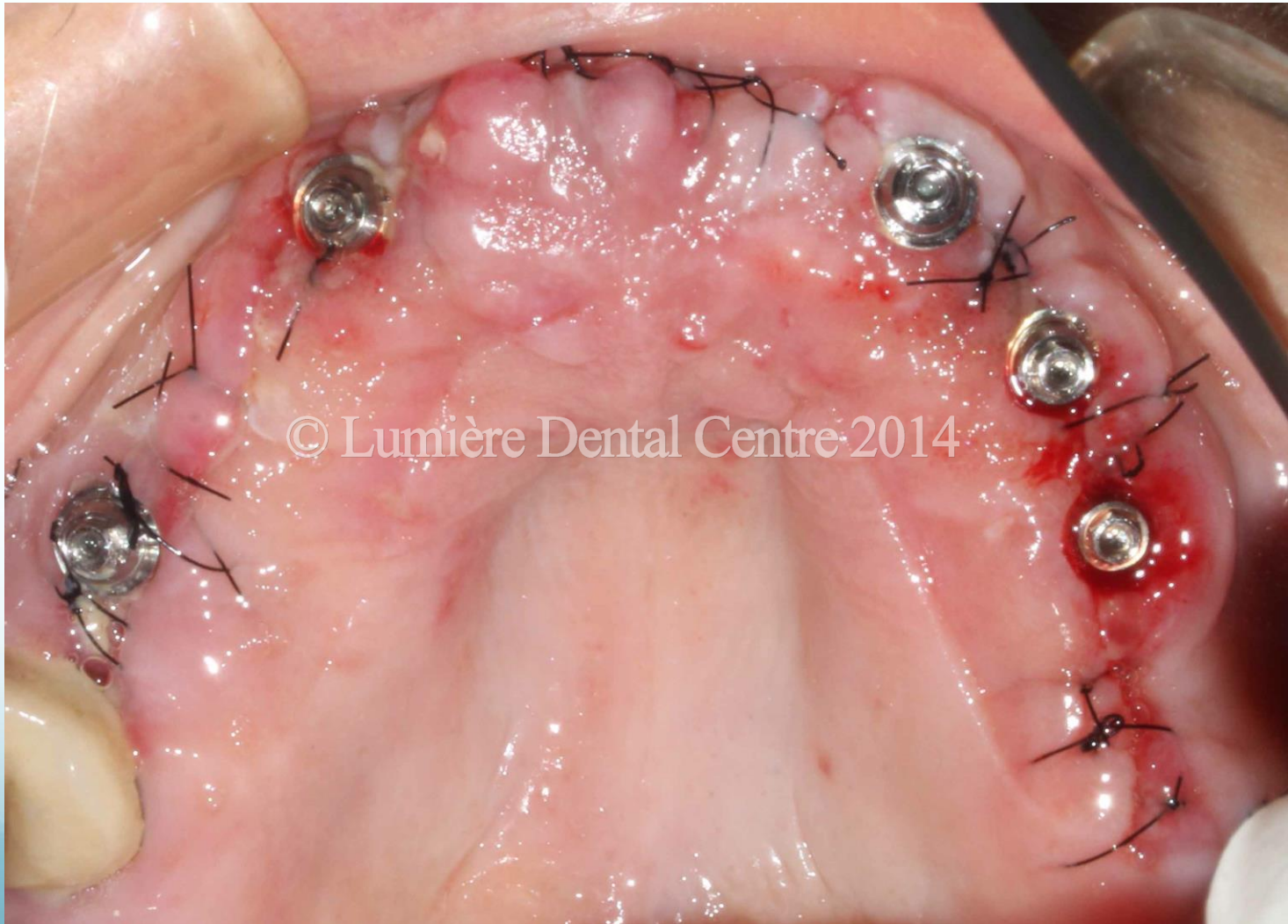Straight Multiunit abutments were used on 5 implants and tightened 15 NCM

After Suturing

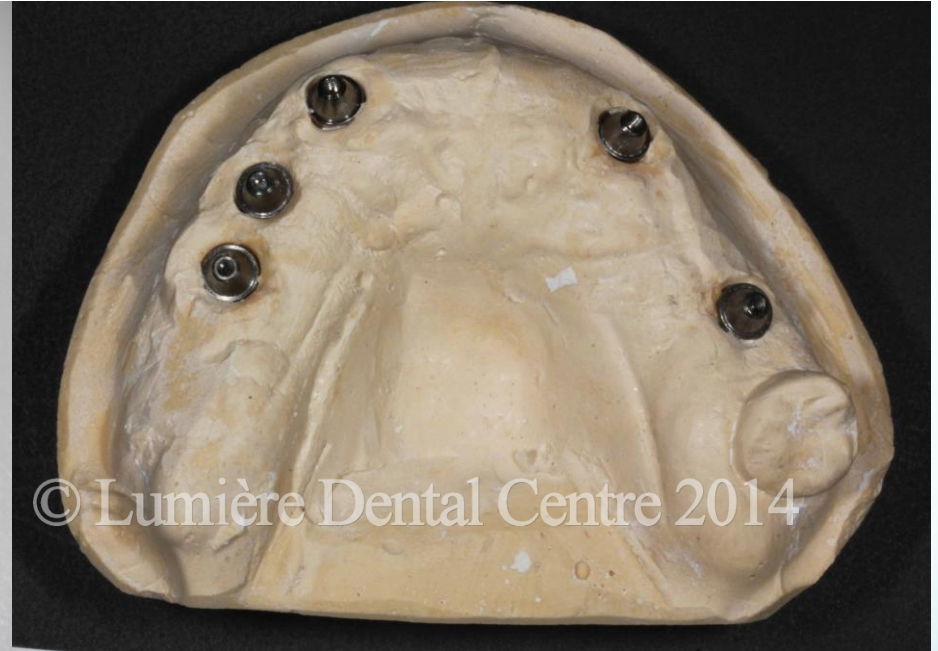
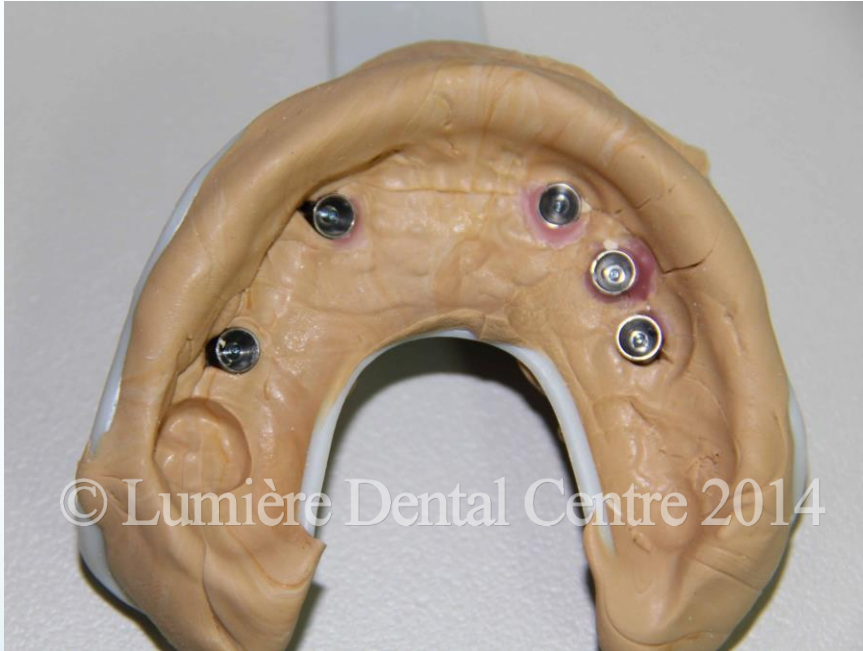
Using 5-0 Nylon , interrupted sutures and continuous anteriorly

After 48 hours



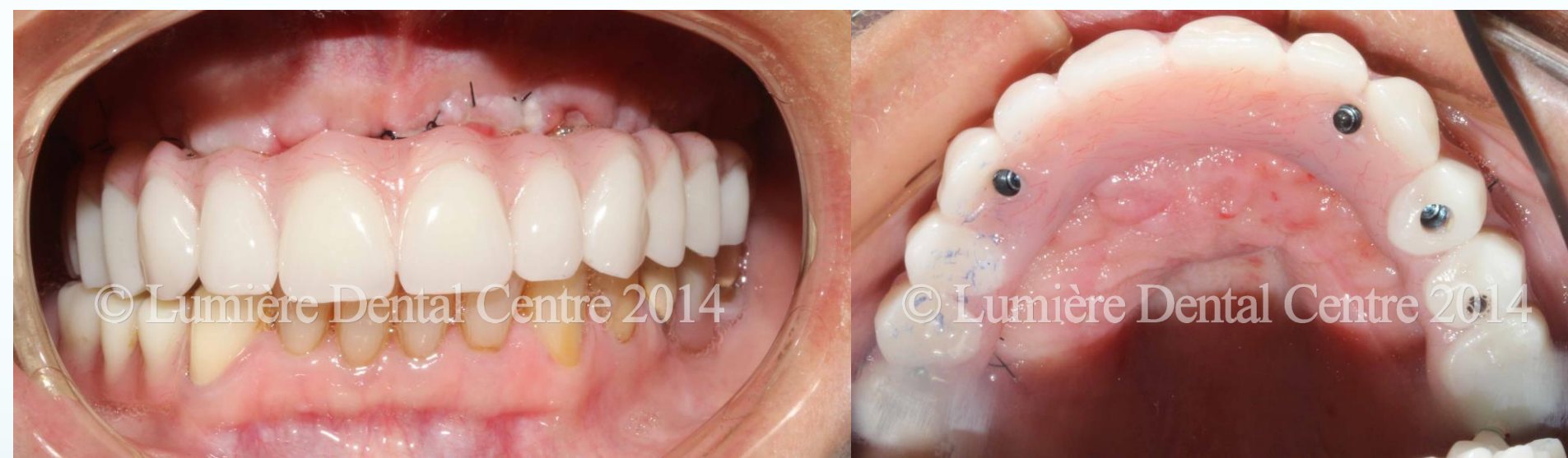Impression and Model



Impression taken 48 hours on abutment level to fabricate the temporary restoration after the surgery using direct open tray impression after splinting of the transfer impression coping using duralay

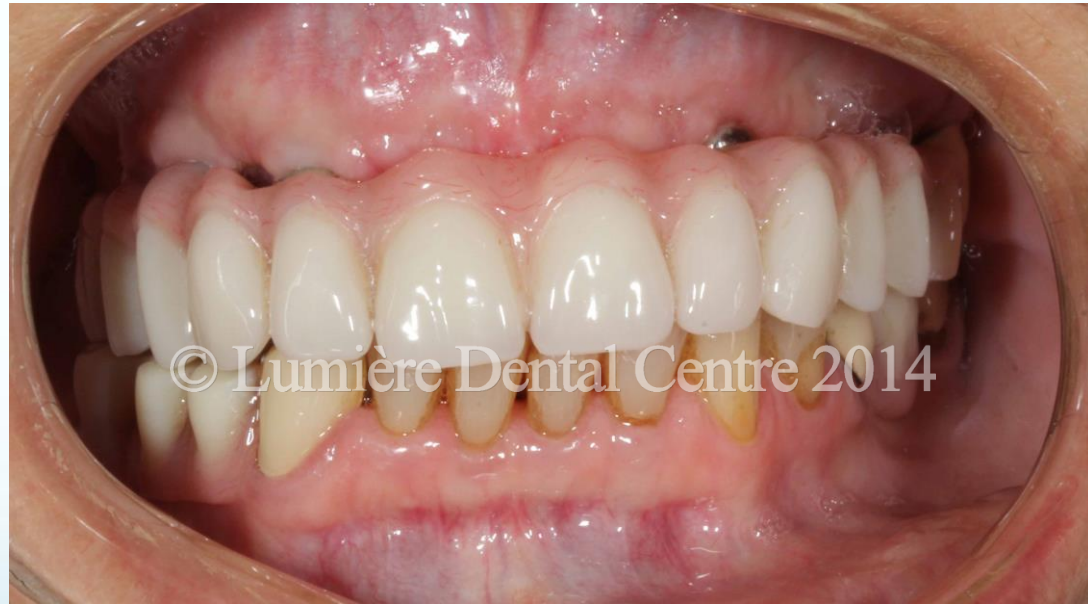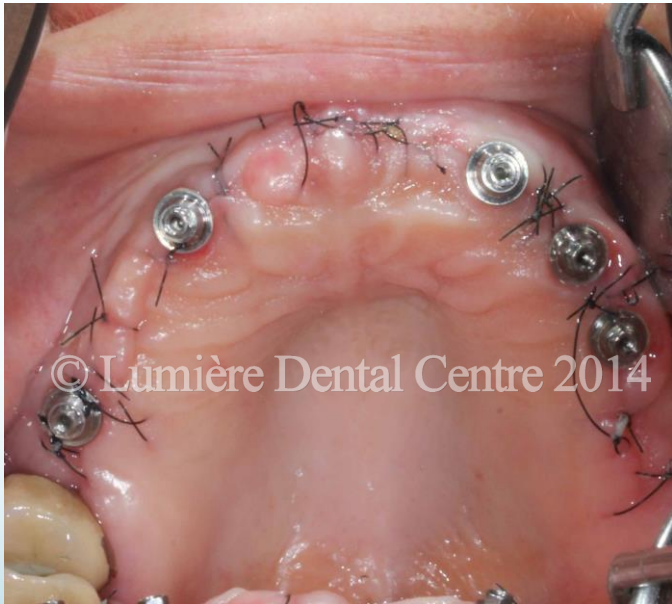The existing denture was used for Jaw relation

Temporary insertion 3 days after surgery



Balanced occlusion and group functioning occlusal scheme

After 15 days



Removal of sutures and recheck occlusion

After Temporary Insertion (3 days post-op)

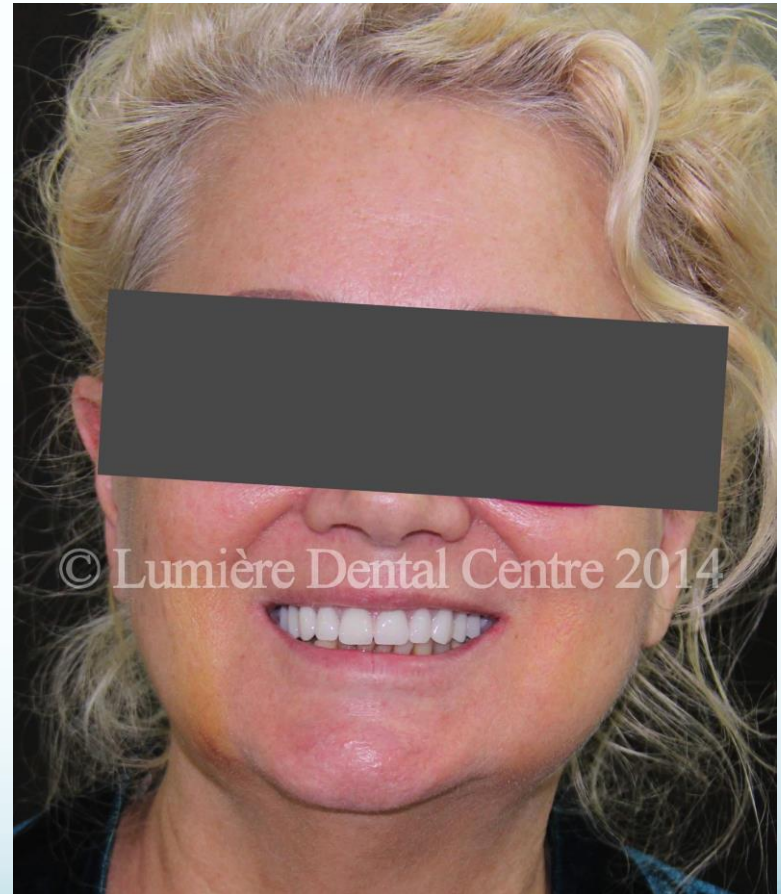Post insertion instructions

Soft food for 21 days

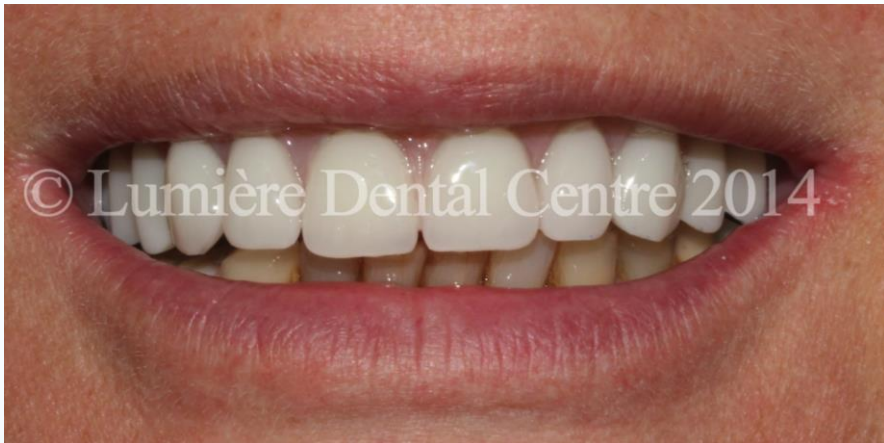Eating both sides .

Using super floss for cleaning
together with water jet cleansing
device (Oxyjet Oral B)

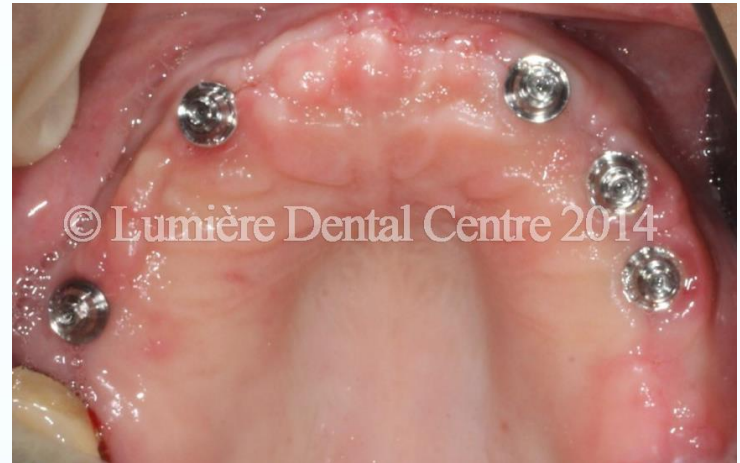Review after 1 months



After 1 month

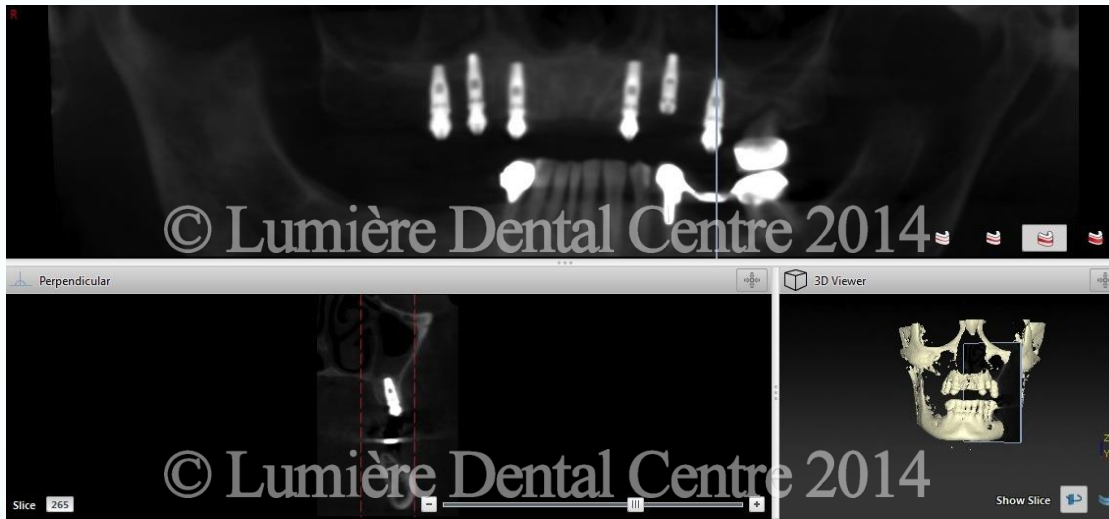


Satisfactory Esthetic outcome

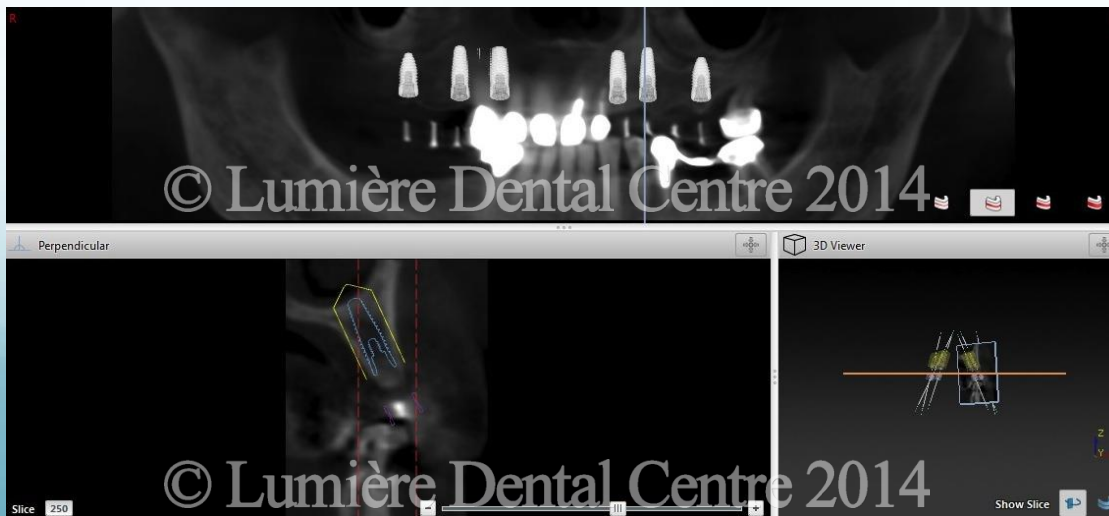


Healthy peri-implant tissues

Comparing initial planning with final result

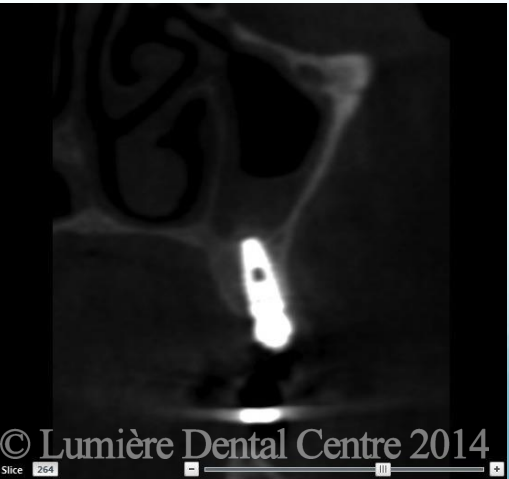
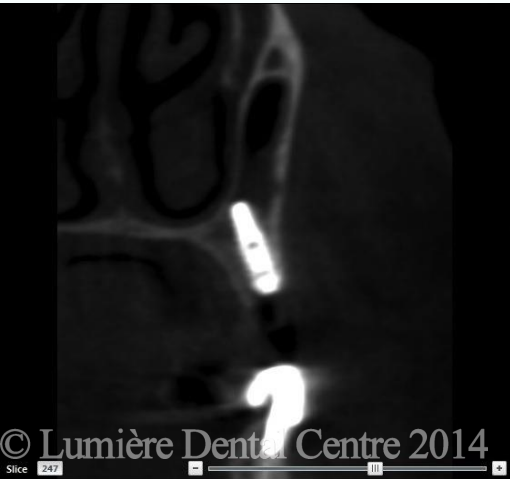
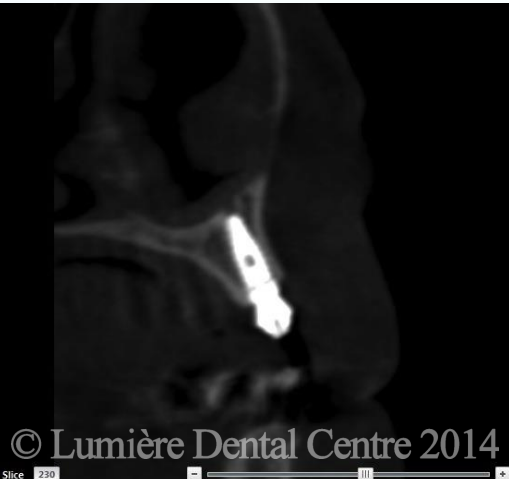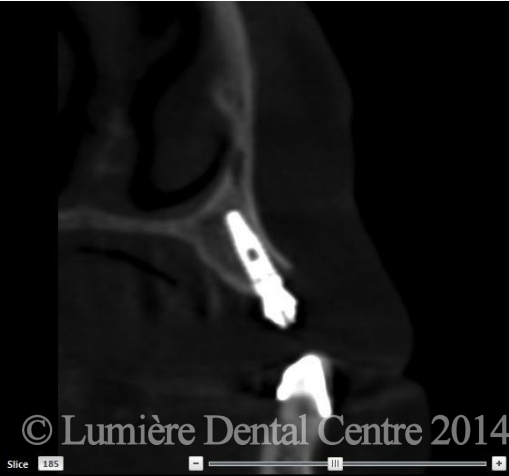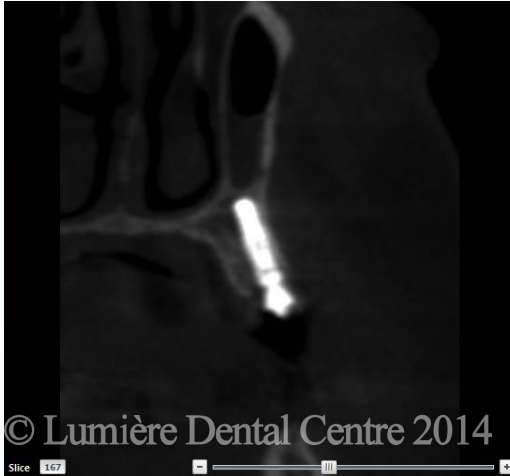


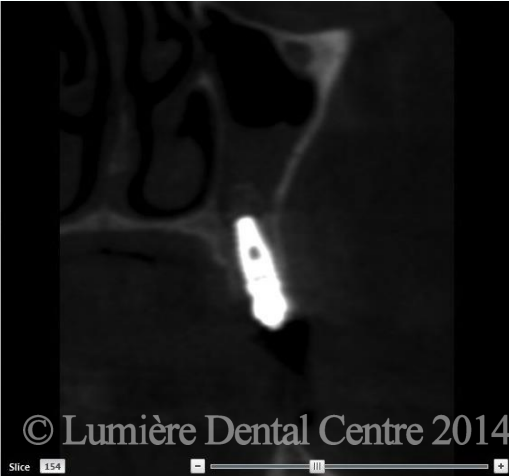CBCT 3 days Post –OP

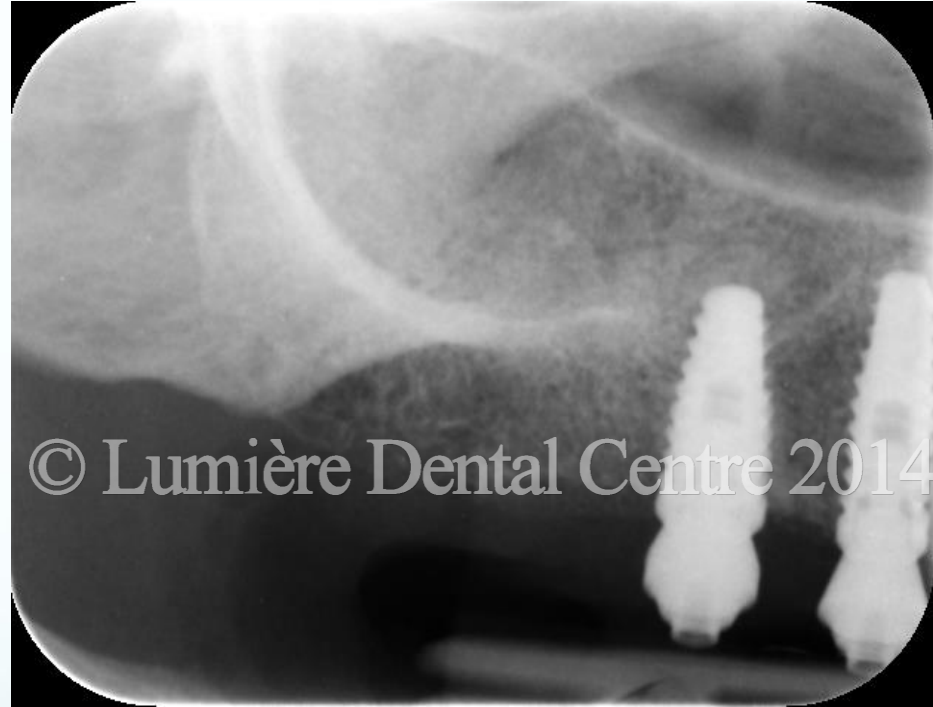
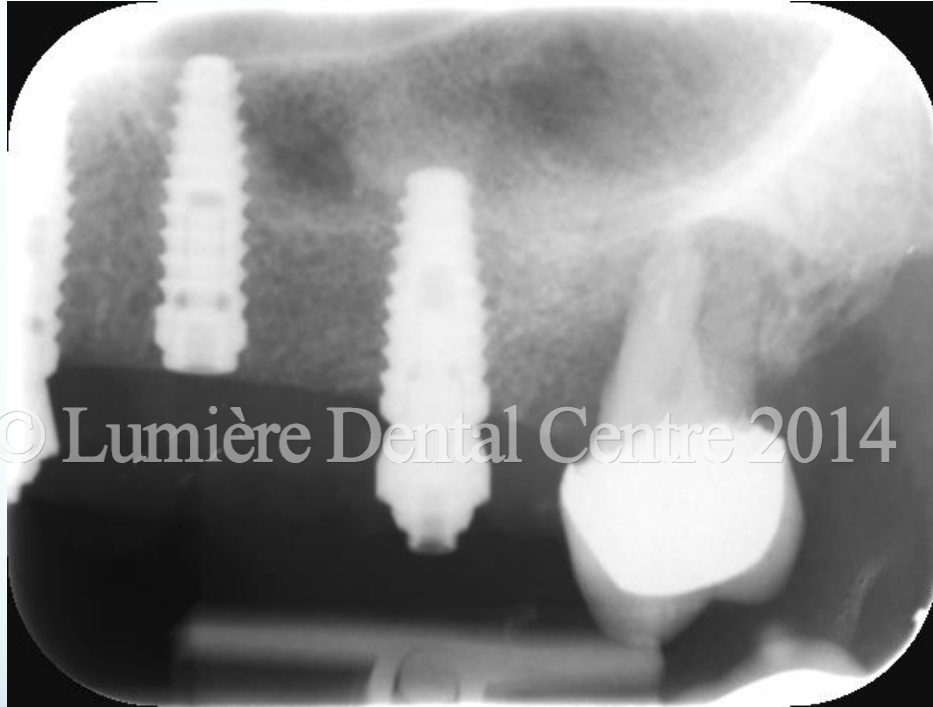
Planning CBCT

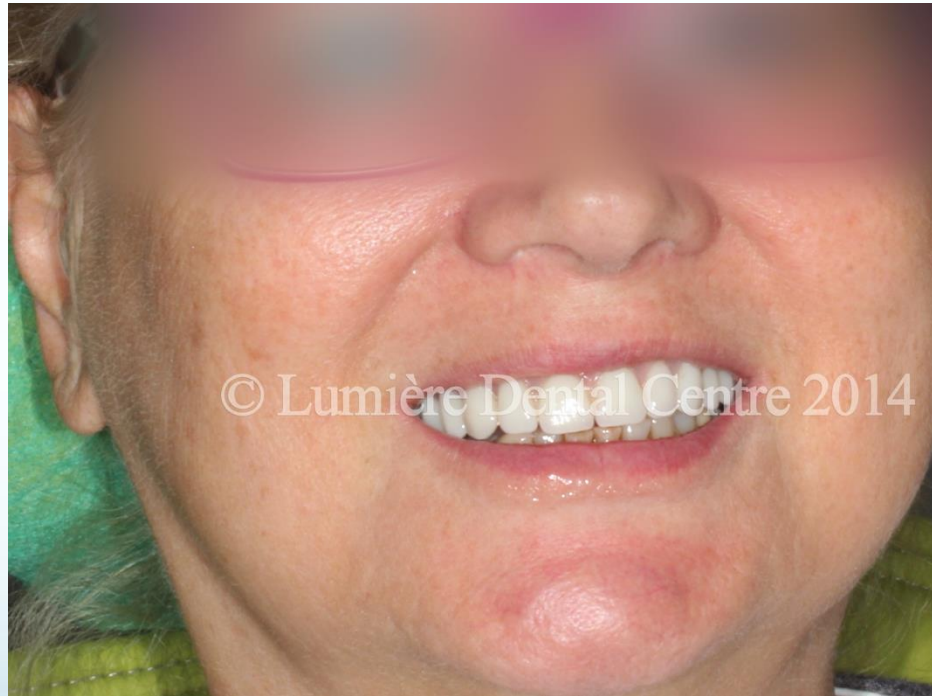Post operative CBCT for each of 6 implants observing internal sinus lifts on the posterior maxilla



Post-op Periapical Radiographs



3 months post-op



References

- Agliardi E, Panigatti S, Clerico M, Villa C, Malo P. Immediate rehabilitation of the edentulous jaws with full fixed prostheses supported by four implants: interim results of a single cohort prospective study. *Clin. Oral Impl. Res.* Xx, 2010; 000-000. doi: 10.1111/j.r600-0501.2009.01852.x
- Kim Y, Oh T-J, Misch CE, Wang H-L. Occlusal considerations in implant therapy: clinical guidelines with biomechanical rationale. *Clin. Oral Impl. Res.* **16** 2005; 26-35 doi: 10.1111/j.1600-0501.2004.01067-x
- NobelBiocare. Nobel_All-on-4_Brochure_2010.1_GB. Manufactures Manual Goeteburg, 2010.
- Agliardi E, Clerico M, Ciancio P, Massironi D. Immediate loading of full-arch fixed prostheses supported by axial and tilted implants for the treatment of edentulous atrophic mandibles. *Quintessence Int* 2010; 41:285-293.
- Capelli M, Zuffetti F, Del Fabbro M, Testori T. Immediate rehabilitation of the completely edentulous jaw with fixed prostheses supported by either upright or tilted implants: a multicenter clinical study. *Int J Oral Maxillofac Implants* 2007; 22:639-644.